

## First case of *Mycobacterium heckeshornense* cavitary lung disease in the Latin America and Caribbean region.

C. Coitinho, G. Greif, J. van Ingen, P. Laserra, C. Robello, C. Rivas

► **To cite this version:**

C. Coitinho, G. Greif, J. van Ingen, P. Laserra, C. Robello, et al.. First case of *Mycobacterium heckeshornense* cavitary lung disease in the Latin America and Caribbean region.. *New Microbes and New Infections*, Wiley Online Library 2016, 9, pp.63-65. 10.1016/j.nmni.2015.12.003 . pasteur-01880473

HAL Id: pasteur-01880473

<https://hal-riip.archives-ouvertes.fr/pasteur-01880473>

Submitted on 24 Sep 2018

**HAL** is a multi-disciplinary open access archive for the deposit and dissemination of scientific research documents, whether they are published or not. The documents may come from teaching and research institutions in France or abroad, or from public or private research centers.

L'archive ouverte pluridisciplinaire **HAL**, est destinée au dépôt et à la diffusion de documents scientifiques de niveau recherche, publiés ou non, émanant des établissements d'enseignement et de recherche français ou étrangers, des laboratoires publics ou privés.



# First case of *Mycobacterium heckeshornense* cavitary lung disease in the Latin America and Caribbean region

C. Coitinho<sup>1</sup>, G. Greif<sup>2</sup>, J. van Ingen<sup>3</sup>, P. Laserra<sup>1</sup>, C. Robello<sup>2,4</sup> and C. Rivas<sup>1</sup>

1) Comisión Honoraria de Lucha Anti-Tuberculosa y Enfermedades Prevalentes (CHLA-EP), 2) Institut Pasteur de Montevideo, Montevideo, Uruguay, 3) Department of Medical Microbiology, Radboud University Medical Center, Nijmegen, The Netherlands and 4) Departamento de Bioquímica, Facultad de Medicina, Universidad de la República, Montevideo, Uruguay

## Abstract

A case of cavitary pulmonary disease caused by *Mycobacterium heckeshornense* in Uruguay is described. This is the first case reported in the Latin America and Caribbean region, showing that this species is a worldwide opportunistic human pathogen.

New Microbes and New Infections © 2015 The Authors. Published by Elsevier Ltd on behalf of European Society of Clinical Microbiology and Infectious Diseases.

**Keywords:** Epidemiology, infection, mycobacterium, *Mycobacterium heckeshornense*, pulmonary

**Original Submission:** 30 October 2015; **Accepted:** 9 December 2015

**Article published online:** 18 December 2015

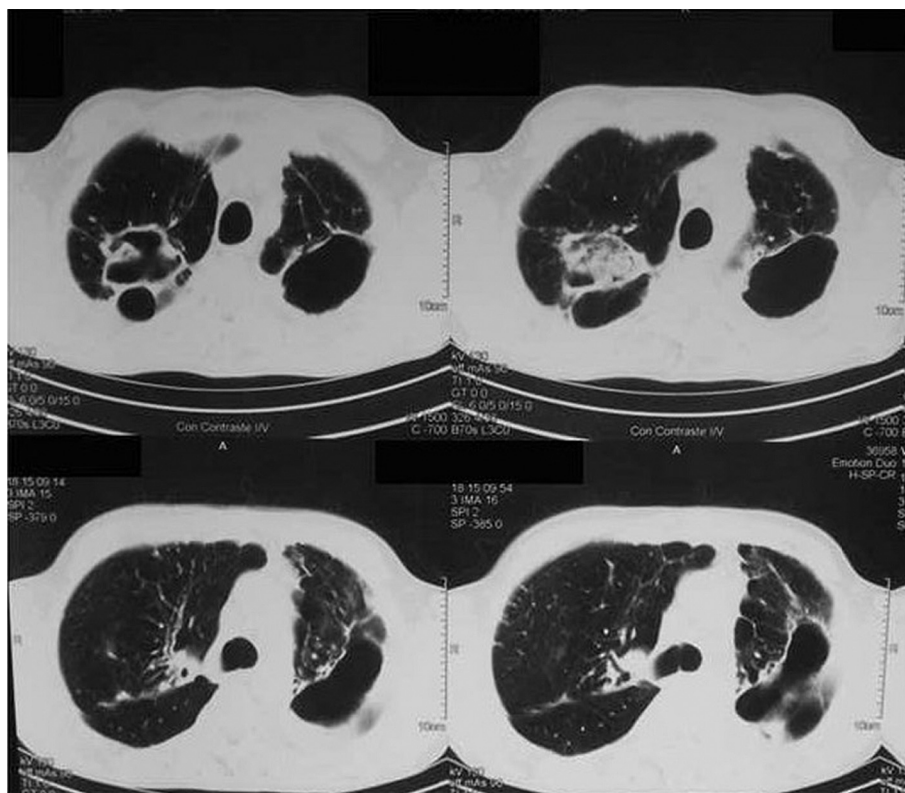
**Corresponding author:** G. Greif, Institut Pasteur de Montevideo, Montevideo, Uruguay  
**E-mail:** [gonzalo.greif@pasteur.edu.uy](mailto:gonzalo.greif@pasteur.edu.uy)

In July 2013 a 53-year-old white homeless man with a history of alcoholism was admitted to the hospital with long-standing cough, fever and fatigue. Physical examination revealed malnutrition with severe weight loss, dyspnea and decreased lung sounds primarily in the upper lobes. Chest radiograph and computed tomographic imaging (Fig. 1) revealed bilateral upper lobe infiltrates with cavitation. Haematological analysis revealed a hemoglobin level of 9.8 g/dL and a leukocyte count of  $6.9 \times 10^9/L$ . HIV serology was negative. With a presumptive diagnosis of tuberculosis, two serial sputum samples and a bronchoalveolar lavage sample were sent to the national tuberculosis reference laboratory. All direct smears (stained with Auramine O and Ziehl-Neelsen) were positive for acid-fast bacilli. Antituberculosis treatment was started, with isoniazid, rifampicin, pyrazinamide and ethambutol (HRZE) provided according to the guidelines of the National Program of Tuberculosis of Uruguay. The bronchoalveolar lavage sample was decontaminated with the N-acetyl-L-cysteine–sodium hydroxide (NALC-NaOH) method and inoculated into mycobacterium growth indicator tubes (MGIT; BD Biosciences,

Sparks, MD, USA) automated liquid culture system. After 26 days of incubation, the MGIT culture flagged positive; Ziehl-Neelsen stain of liquid culture was positive for acid-fast bacilli, and immunochromatographic test for the identification of *Mycobacterium tuberculosis* complex (TBC ID; Becton Dickinson, Franklin Lakes, NJ, USA) was negative. Cells were pelleted and DNA extracted. The GenoType Mycobacterium CM (common mycobacteria) and AS (additional species) assays (Hain Lifesciences, Nehren, Germany) for identification of nontuberculous mycobacteria were performed. The results were positive for *M. heckeshornense*.

Subcultures on Ogawa medium, as well as the solid cultures from the two sputum samples, yielded small, hemispheric, smooth and yellow-pigmented colonies after 4 weeks of incubation.

Phenotypic characterization was performed for all isolates (Table 1), and DNA was submitted to the Institut Pasteur at Montevideo for sequencing studies. To identify the isolates to the species level, the complete 16S rDNA gene and a fragment of *hsp65* and *rpoB* genes were sequenced (GenBank accession numbers KP636957, KP636958 and KP636959, respectively). The DNA sequences obtained were compared with the GenBank/European Molecular Biology Laboratory sequence database. Gene sequencing unambiguously confirmed the identification of *M. heckeshornense* (100%



**FIG. 1.** Chest computed tomographic scan showing pulmonary infiltrates and cavities.

similarity with *M. heckeshornense* type strain sequences for all targets). With these clinical, radiologic and microbiologic findings, the patient met the American Thoracic Society/Infectious Diseases Society of America diagnostic criteria of nontuberculous mycobacterial lung disease [1]. Treatment was thus changed to isoniazid, rifampicin, ethambutol, levofloxacin and clarithromycin, all provided daily. Ethambutol had to be stopped owing to ocular toxicity. The patient improved clinically, and a regression of the lesions was observed radiologically. After 12 months of treatment with the

macrolide-containing regimen, the patient had converted to negative cultures, and treatment was stopped. After 12 months of follow-up, his disease is clinically and radiologically stable and culture negative.

*M. heckeshornense* was first reported in 2000 as a pathogenic, slowly growing scotochromogenic mycobacterium, phylogenetically related to *Mycobacterium xenopi*, that caused a bilateral cavitary lung disease in an immunocompetent patient [2]. Since then, a limited number of cases were reported in humans, some of them involving severe pulmonary infections [3–5] often

**TABLE I.** Phenotypic characteristics of isolates from Uruguay and isolates originally reported as *Mycobacterium heckeshornense* sp.

| Feature                      | <i>Mycobacterium xenopi</i> | Isolates from Uruguay (n = 3) | Isolates of <i>M. heckeshornense</i> sp. nov. <sup>a</sup> |                |                |
|------------------------------|-----------------------------|-------------------------------|--|----------------|----------------|
|                              |                             |                               | S369   | S532           | S504           |
| Morphology                   | Smooth                      | Smooth                        | Smooth   | Smooth         | Smooth         |
| Pigment                      | Scotochromogen              | Scotochromogen                | Scotochromogen   | Scotochromogen | Scotochromogen |
| Growth rate                  | Slow                        | Slow                          | Slow   | Slow           | Slow           |
| Growth at 37°C               | +                           | +                             | +  | +              | +              |
| Growth at 42°C               | +                           | +                             | +  | +              | +              |
| Niacin production            | –                           | –                             | –  | –              | –              |
| Nitrate reduction            | –                           | –                             | –  | –              | –              |
| Catalase (heat stable)       | –/+                         | +                             | +  | +              | +              |
| Arylsulfatase 3 days/14 days | + (weak)/+                  | + (weak)/+                    | –/–  | –/–            | –/–            |
| Pyrazinamide                 | +                           | +                             | –  | –              | –              |
| Tween 80 hydrolysis          | –                           | –                             | –  | –              | –              |

<sup>a</sup>Identification number of isolates obtained by Roth *et al.* [5].

identified as *M. xenopi* and also involving extrapulmonary infections [6–12]. Furthermore, it was isolated from animal sources such as porcine lymph nodes [13] and from a domestic cat with a severe generalized infection [14]. This could indicate that this species is widely distributed in the environment. The new commercially available molecular biology methods can fast and precisely identify most common *Mycobacterium* species. In our case, we identified correctly *M. heckeshornense* using the Genotype CM/AS HAIN tests in 2 days.

The patient was treated with standard therapy (HRZE) for 2 months, until the diagnosis of *M. heckeshornense* was confirmed. In the absence of guidelines for the treatment of *M. heckeshornense* disease, the patient was treated with isoniazid, rifampicin, ethambutol, levofloxacin and clarithromycin. This led to prolonged culture conversion and no relapse 12 months after treatment cessation. In some patients [5,7], resolution was reached with surgical procedures. In our case, the extent of the pulmonary lesions and the general condition of the patient prevented this approach. Although *M. heckeshornense* is genetically related to *M. xenopi*, its pathogenicity is noticeably higher [4]. Cases have been reported in Asia, Europe and recently in Canada [7], showing that *M. heckeshornense* is an opportunistic pathogen present worldwide. This is the first case reported in Uruguay and the Latin America and Caribbean regions. A possible explanation of this fact is that in many countries of this region, tuberculosis disease is confirmed only by microscopy; culture and identification, particularly molecular identification, are not routinely done.

In summary, we describe a case of fibrocavitary *M. heckeshornense* pulmonary disease, the first of its kind described in the Latin America and Caribbean region. A treatment regimen of isoniazid, rifampicin, clarithromycin and levofloxacin led to symptomatic improvement. *M. heckeshornense* is a serious nontuberculous mycobacterial pathogen with a worldwide spread.

## Acknowledgements

Partially funded by FOCEM (MERCOSUR Structural Convergence Fund), grant COF 03/11. GG, CR and CC are researchers from the Sistema Nacional de Investigadores (ANII), Uruguay.

## Conflict of Interest

None declared.

## References

- [1] Griffith DE, Aksamit T, Brown-Elliott BA, Catanzaro A, Daley C, Gordin F, et al. An official ATS/IDSA statement: diagnosis, treatment, and prevention of nontuberculous mycobacterial diseases. *Am J Respir Crit Care Med* 2007;175:367–416.
- [2] Morimoto K, Kazumi Y, Maeda S, Yoshimori K, Yoshiyama T, Ogata H, et al. *Mycobacterium heckeshornense* lung infection that was diagnosed as *Mycobacterium xenopi* disease by DNA-DNA hybridization (DDH). *Intern Med* 2011;50(11):1251–3. Epub 2011 Jun 1.
- [3] Hisamoto A, Ozaki S, Sakugawa M, Komoto R, Tamaoki A, Miyake T, et al. [A possible case of pulmonary infection due to *Mycobacterium heckeshornense*]. *Nihon Kokyuki Gakkai Zasshi* 2008;46:1019–23.
- [4] Jauregui F, Ios V, Marzouk P, Hornstein M, Picard B, Gutierrez MC, et al. *Mycobacterium heckeshornense*: an emerging pathogen responsible for a recurrent lung infection. *J Infect* 2007;54:e33–5.
- [5] Roth A, Reischl U, Schonfeld N, Naumann L, Emler S, Fischer M, et al. *Mycobacterium heckeshornense* sp. nov., a new pathogenic slowly growing *Mycobacterium* sp. causing cavitory lung disease in an immunocompetent patient. *J Clin Microbiol* 2000;38:4102–7.
- [6] Ahmed RA, Miedzinski LJ, Shandro C. *Mycobacterium heckeshornense* infection in HIV-infected patient. *Emerg Infect Dis* 2010;16:1801–3.
- [7] Chan WW, Murray MC, Tang P, Romney MG. *Mycobacterium heckeshornense* peritonitis in a peritoneal dialysis patient: a case report and review of the literature. *Clin Microbiol Infect* 2011;17:1262–4.
- [8] Elyousfi AA, Leiter JR, Goytan MJ, Robinson DB. *Mycobacterium heckeshornense* lumbar spondylodiskitis in a patient with rheumatoid arthritis receiving etanercept treatment. *J Rheumatol* 2009;36:2130–1.
- [9] Godreuil S, Marchandin H, Terru D, Le Moing V, Chammas M, Vincent V, et al. *Mycobacterium heckeshornense* tenosynovitis. *Scand J Infect Dis* 2006;38:1098–101.
- [10] McBride SJ, Taylor SL, Pandey SK, Holland DJ. First case of *Mycobacterium heckeshornense* lymphadenitis. *J Clin Microbiol* 2009;47:268–70.
- [11] Kazumi Y, Sugawara I, Wada M, Kimura K, Itono H. [Microbiologically identified isolates of *Mycobacterium heckeshornense* in two patients]. *Kekkaku* 2006;81:603–7.
- [12] van Hest R, van der Zanden A, Boeree M, Kremer K, Dessens M, Westenend P, et al. *Mycobacterium heckeshornense* infection in an immunocompetent patient and identification by 16S rRNA sequence analysis of culture material and a histopathology tissue specimen. *J Clin Microbiol* 2004;42:4386–9.
- [13] van Ingen J, Wisselink HJ, van Solt-Smits CB, Boeree MJ, van Soolingen D. Isolation of mycobacteria other than *Mycobacterium avium* from porcine lymph nodes. *Vet Microbiol* 2010;144:250–3.
- [14] Elze J, Grammel L, Richter E, Aupperle H. First description of *Mycobacterium heckeshornense* infection in a feline immunodeficiency virus-positive cat. *J Feline Med Surg* 2013;15:1141–4.